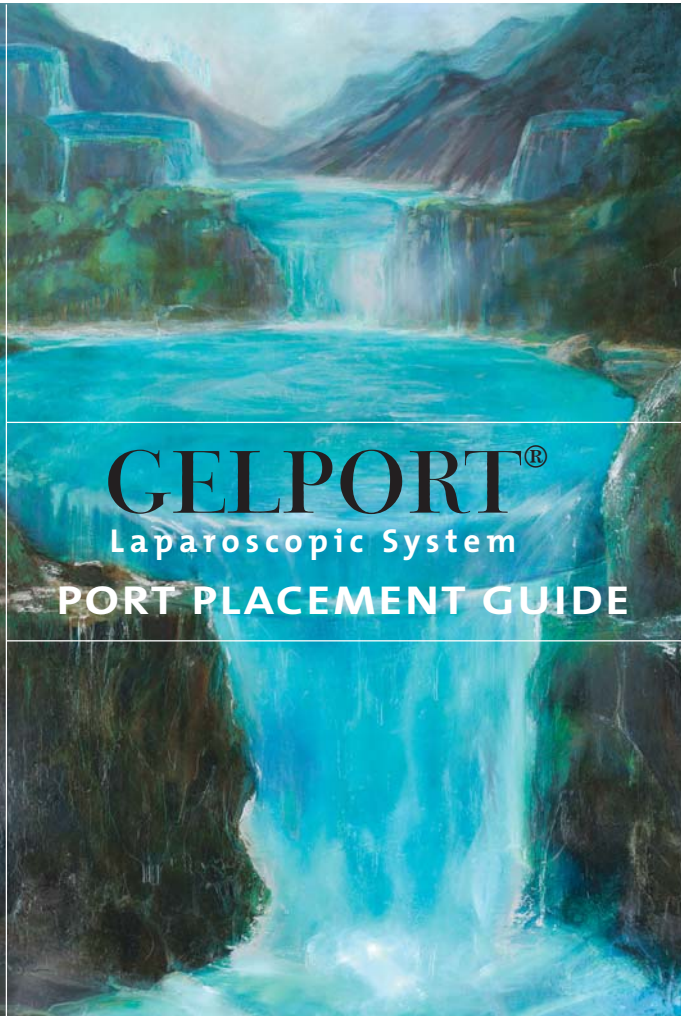


ELEGANT SOLUTIONS

GELPORT[®]

Laparoscopic System

PORT PLACEMENT GUIDE



INTRODUCTION

As a consultant for several leading surgical companies, I often have the opportunity to evaluate and assess new equipment. I typically divide new products into two categories: “a revolutionary technology” and “a technology looking for an indication.” For the past decade, several new devices have helped advance the practice of surgery and, specifically, laparoscopic colorectal surgery. I found the one that has impacted me the most has been the development of the GelPort® system.

The ability to teach residents and attending surgeons the technique of laparoscopic hand access colectomy with the GelPort system has been phenomenal. The ability to maintain pneumoperitoneum and quickly switch between straight laparoscopic, hand access, and open techniques has revolutionized my practice and my way of teaching surgeons and residents.

The product, when compared to other hand devices, is unique. It allows you to easily adjust for different abdominal wall heights, provides superior lateral retraction of the wound and allows for easy hand exchanges without loss of pneumoperitoneum.

Over the past 5 years, I have performed numerous studies of hand access laparoscopic colorectal surgery, including comparative and randomized controlled trials. A group of us, colorectal surgeons from Lahey Clinic, Washington University in St. Louis, Cornell – New York Hospital, Columbia – Presbyterian Hospital, and Western Pennsylvania Hospital, have completed a prospective randomized study comparing straight laparoscopic and hand access colectomy. While the trial results have yet to be published, the study did show a reduction in operative time for both segmental colon resection and total colectomy. We also saw fewer conversions in the hand access cases. Postoperative parameters such as pain scores, narcotic usage, return of bowel function, and length of stay were similar between the two groups. This study, along with others, confirms that the hand access approach maintains the advantages of a minimally invasive operation with unparalleled versatility when compared with straight laparoscopic techniques.

We hope that you will find the diagrams for port placement helpful to you. While each of us uses a slightly different approach, the themes are common. In general, for left-sided colon resections or a total colectomy we use a lower midline incision or Pfannenstiel incision for the hand device placement. This allows the incision to be over the site of the future anastomosis and allows the hand to enter the abdomen without obstructing the view. The camera is typically placed above the umbilicus and several ports are placed laterally. The port placement allows both for a medial and lateral approach to colon mobilization and allows the opportunity to perform straight laparoscopic surgery with instruments passed directly through the GelSeal® cap cover.

Peter W. Marcello, MD, FACS, FASCRS

SURGEON ADVISORS



Peter W. Marcello, MD, FACS, FASCRS
Staff Surgeon
Department of Colon & Rectal Surgery
Lahey Clinic
Burlington, MA



Matthew G. Mutch, MD, FACS, FASCRS
Assistant Professor of Surgery
Section of Colon & Rectal Surgery
Barnes Jewish Hospital
Washington University School of Medicine
St. Louis, MO



Thomas E. Read, MD, FACS, FASCRS
Chief, Division of Colon & Rectal Surgery
Program Director, Colon & Rectal Surgery Residency
Western Pennsylvania Hospital
Pittsburgh, PA
Associate Professor of Surgery
Temple University School of Medicine



David E. Rivadeneira, MD, FACS, FASCRS
Assistant Professor of Surgery
Division of Surgical Oncology and
Colon and Rectal Surgery
State University of New York at Stony Brook
Stony Brook, New York



Jay Singh, MD, FACS, FASCRS
Director, Surgical Residency
Piedmont Hospital
Associate Professor, Emory University
Atlanta, GA

Applied Medical would like to thank the above surgeons for their contributions to this guide.

POSITIONING

PATIENT

Suggested patient positioning:

- ◆ Place patient in Lithotomy position with arms tucked for all procedures.
- ◆ Position stirrups so that thighs extend 0 to 10 degrees, which facilitates dissection of flexures and transverse colon.

SURGEON

Surgeon positioning is dependent on factors such as the anatomy, access and site pathology. Therefore, where to stand is at the surgeon's discretion, and may often change during the procedure.



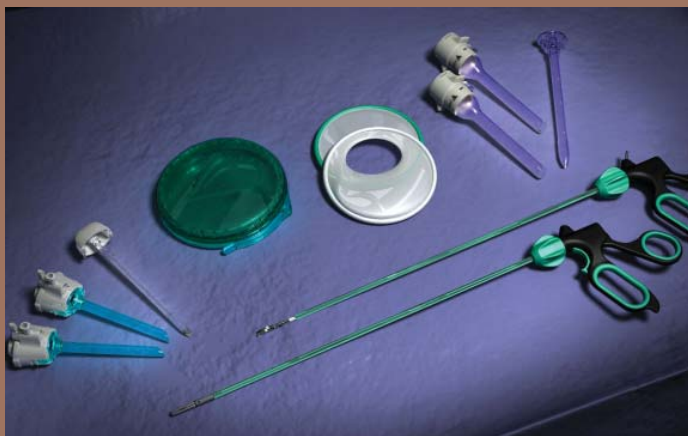PATIENT & SURGEON POSITIONING

BASIC INSTRUMENTATION

- ◆ GelPort® laparoscopic system
- ◆ 2, 10 - 12mm trocars
- ◆ 2 - 3, 5mm trocars
- ◆ Laparoscope
- ◆ Laparoscopic graspers
- ◆ Energy ligation device for dissection/hemostasis
- ◆ Instruments for division of major vessels: staplers, clips, etc.

AUXILIARY INSTRUMENTATION TO BE USED AS NEEDED

- ◆ Laparoscopic scissors
- ◆ Circular stapler
- ◆ Open linear stapler: 45mm or 55mm
- ◆ Endoscopic stapler: 30mm, 45mm or 60mm
(Loaded with cartridge:
2.0mm, 2.5mm, 3.5mm or 4.8mm)



RIGHT COLECTOMY

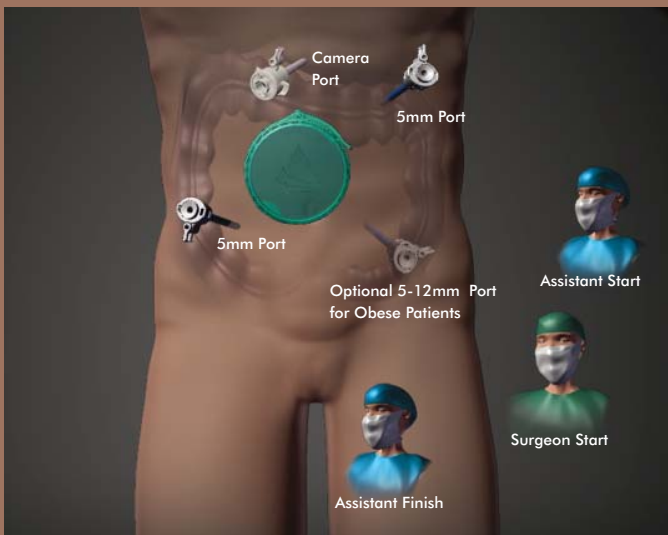
Mobilization approach: medial to lateral, then superior to inferior, then inferior to superior (minimizes Trendelenburg position time)

- ◆ Place ports. Introduce GelPort® system, if using.
- ◆ Tilt body to the left, otherwise neutral
- ◆ Sweep small bowel into pelvis
- ◆ Grasp mesentery adjacent to ileocecal valve and elevate toward right hip
- ◆ Identify ileocolic vessels
- ◆ Incise peritoneum around root of ileocolic vessels
- ◆ Separate mesocolon from retroperitoneum (“purple goes down”)
- ◆ Separate duodenum from mesocolon and ileocolic vessels
- ◆ Divide ileocolic vessels
- ◆ Continue separation of mesocolon from retroperitoneum (“purple goes down”) over duodenum and pancreas, mobilizing hepatic flexure from underneath. Continue separation inferiorly, but be cautious with retraction to avoid injury to arcades in terminal ileal mesentery
- ◆ Reverse Trendelenburg position
- ◆ Separate omentum from transverse colon and superior portion of transverse mesocolon, or divide omentum (goal is to get into avascular plane between omentum and transverse mesocolon and separate this fusion plane)
- ◆ Divide remaining attachments of hepatic flexure
- ◆ Continue division of lateral attachments of ascending colon to pelvic brim
- ◆ May divide right branch of middle colic vessels at this point, if necessary
- ◆ Trendelenburg position
- ◆ Sweep small bowel out of pelvis into upper abdomen
- ◆ Mobilize terminal ileal mesentery from retroperitoneum, from lateral pelvic brim to midline, thus exposing duodenum from inferior view
- ◆ Divide remaining lateral attachments
- ◆ Check mobility: colon should now be returned to embryologic midline position
- ◆ Check for hemostasis
- ◆ Close port sites
- ◆ Return colon to anatomic position
- ◆ Grasp mesentery adjacent to ileocecal valve
- ◆ Enlarge umbilical port site
- ◆ If using GelPort system remove GelSeal® cap
- ◆ Deliver bowel to anterior abdominal wall in correct orientation
- * If bowel will not come through opening, enlarge incision or deliver ileum, divide mesentery and ileum, tag with suture, return to abdomen, then deliver colon
- ◆ Divide ileal mesentery and transverse mesocolon
- ◆ Divide bowel (after mesentery divided to avoid twisting)
- ◆ Construct anastomosis and check

RIGHT COLECTOMY USING THE GELPORT SYSTEM

Other instrumentation:

- Laparoscopic grasper
- Laparoscopic scissors
- Energy ligation device
- Endoscopic stapler

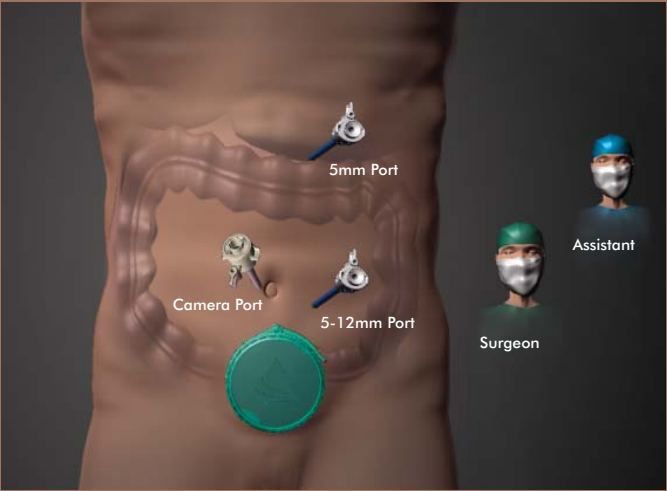


RIGHT COLECTOMY

RIGHT COLECTOMY WITH ILEOCOLIC RESECTION USING GELPORT® SYSTEM

Other instrumentation:

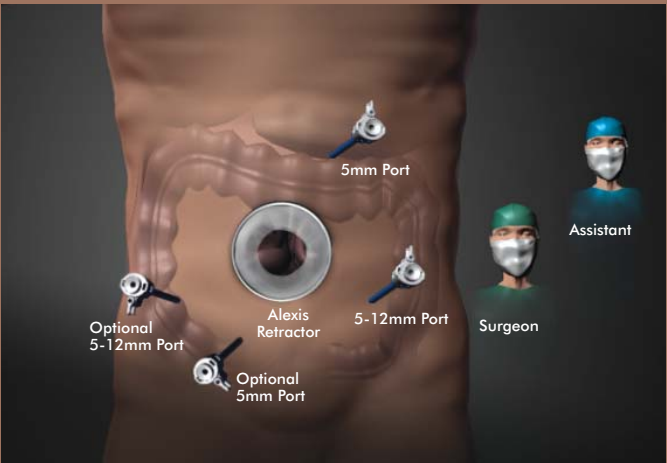
- Laparoscopic grasper
- Energy ligation device
- Endoscopic stapler for lateral to medial dissection and extracorporeal anastomosis



RIGHT COLECTOMY USING ALEXIS® WOUND RETRACTOR

Other instrumentation:

- Laparoscopic grasper
- Laparoscopic scissors
- Energy ligation device
- Open linear stapler



RIGHT COLECTOMY

LEFT COLECTOMY USING GELPORT® SYSTEM SIGMOID, LOW ANTERIOR, RECTAL

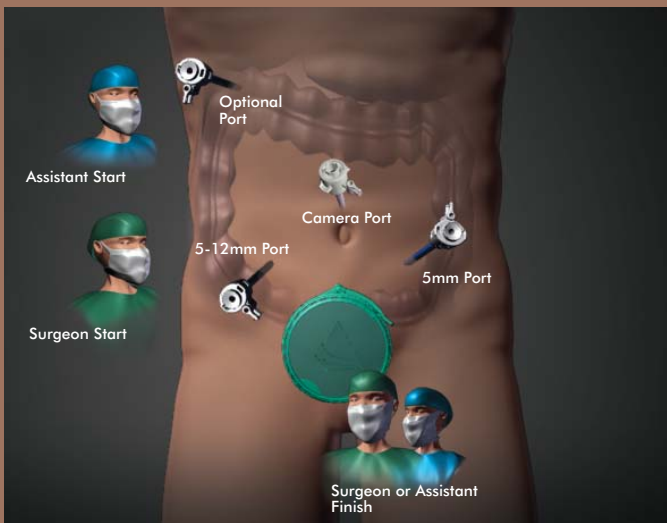
Mobilization approach: medial to lateral

- ◆ Make Pfannensteil incision (7-8 cm)
- ◆ Place Alexis® O™ wound retractor
- ◆ Begin dissection through open wound
- ◆ Place supraumbilical camera port and RLQ 12mm port under direct vision
- ◆ Attach GelSeal® cap and establish pneumoperitoneum
- ◆ Place 5mm ports in RUQ and LLQ
- ◆ Body tilted to the right, Trendelenburg position
- ◆ Sweep small bowel out of pelvis and cover with laparotomy pad
- ◆ Elevate right side of sigmoid mesocolon and identify arc of superior hemorrhoidal vessels
- ◆ Incise peritoneum just deep to superior hemorrhoidal vessels from IMA origin into pelvis (over sacral promontory along right side of mesorectum)
- ◆ Separate mesocolon from retroperitoneum ("purple goes down"), taking care not to divide posteriorly after going under superior hemorrhoidal vessels
- ◆ Identify and stay anterior to ureter, gonads, iliac vessels
- ◆ Isolate and divide IMA at its origin, or superior hemorrhoidal vessels at their origin if left colon redundant
- ◆ Continue separation of mesocolon from retroperitoneum ("purple goes down") superiorly to tail of pancreas, mobilizing splenic flexure from underneath. Stay deep to IMV (unless IMA not divided at its origin)
- ◆ Slight reverse Trendelenburg position
- ◆ Isolate and divide IMV at ligament of Treitz
- ◆ Separate omentum from transverse colon and transverse mesocolon toward the midline
- ◆ Divide remaining attachments of splenic flexure
- ◆ Trendelenburg position
- ◆ Divide lateral attachments of left colon, continuing inferiorly into the pelvis along the left side of the mesorectum
- ◆ Mobilize mesorectum
- ◆ Confirm mobility of proximal colon
- ◆ Check hemostasis
- ◆ May divide mesorectum and rectum using laparoscopic approach now (useful if patient obese and view through Pfannensteil limited)... otherwise...
- ◆ Deflate pneumoperitoneum by removing GelSeal cap
- ◆ Separate rectum from mesorectum
- ◆ Divide rectum using laparoscopic stapler through RLQ port, or through incision
- ◆ Divide mesorectum
- ◆ Exteriorize proximal colon
- ◆ Divide descending colon mesentery just proximal to IMA tie
- ◆ Divide descending colon and place anvil of stapler
- ◆ Create anastomosis and test
- ◆ Close large port sites (may be done through incision)
- ◆ Close incisions

LEFT COLECTOMY USING GELPORT SYSTEM SIGMOID ■ LOW ANTERIOR ■ RECTAL

Other instrumentation:

- Laparoscopic grasper
- Endoscopic stapler
- Circular stapler
- Energy ligation device



LEFT COLECTOMY

TOTAL COLECTOMY OR PROCTOCOLECTOMY USING GELPORT® SYSTEM

Mobilization approach: medial to lateral

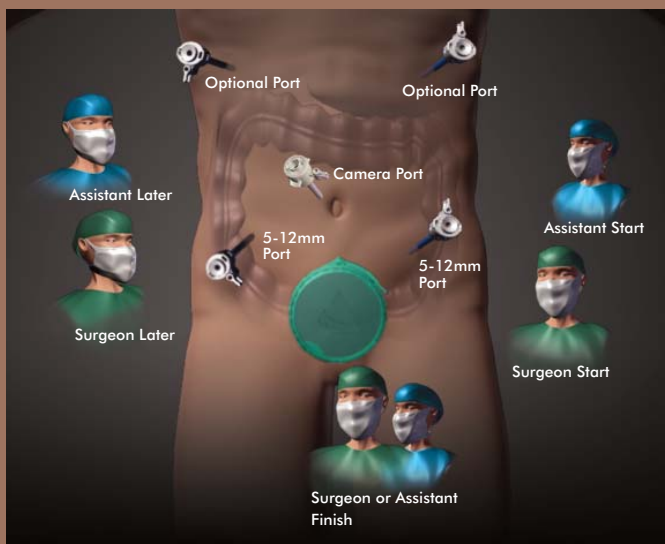
Begin with the right and transverse HALS procedures, see instructions for "RIGHT COLECTOMY."

Once the right and transverse colon are devascularized and fully mobilized proceed with the HALS left colectomy, see instructions for "LEFT COLECTOMY."

Once the splenic flexure and distal transverse colon are mobilized proceed with an open rectal transection or rectal mobilization, if proctectomy is necessary. Rectal mobilization can be done via HALS or open through the GelPort system site.

Other instrumentation:

- Laparoscopic grasper
- Open linear stapler
- Endoscopic stapler
- Circular stapler
- Energy ligation device





22872 Avenida Empresa Rancho Santa Margarita CA 92688
www.appliedmedical.com

To place an order or for more information call 800.282.2212

©2007 Applied Medical Resources Corporation. All rights reserved.
Applied Medical, the Applied Medical logo design, GelPort and Alexis are
registered trademarks of Applied Medical Resources Corporation.
Patient positioning, equipment and port placements are suggestions only
and may vary according to patient need and surgeon preference. SC01318B